

UNCLASSIFIED


AD NUMBER
AD836149
NEW LIMITATION CHANGE
TO Approved for public release, distribution unlimited
FROM Distribution authorized to U.S. Gov't. agencies and their contractors; Administrative/Operational Use; 2 Oct 1963. Other requests shall be referred to Department of the Army, Fort Detrick, MD.
AUTHORITY
SMUFD D/A ltr, 8 Feb 1972

THIS PAGE IS UNCLASSIFIED


AD836149

TRANSLATION NO. 847

DATE: 2 Jul 1963




JUL 20 1966



DEPARTMENT OF THE ARMY
Fort Detrick
Frederick, Maryland

DISCLAIMER NOTICE



THIS DOCUMENT IS BEST QUALITY AVAILABLE. THE COPY FURNISHED TO DTIC CONTAINED A SIGNIFICANT NUMBER OF PAGES WHICH DO NOT REPRODUCE LEGIBLY.

REPRODUCED FROM
BEST AVAILABLE COPY

HISTOPLASMOSIS WITH FATAL RESULTS AS AN OCCUPATIONAL DISEASE
OF A MYCOLOGIST^W

Following is the translation of an article by
M. Hartung and K. Salfelder in the German-language
publication Int. Archiv fuer Gewerbepathologie und
Gewerbehygiene (Int. Archives for Industrial Patho-
logy and Industrial Hygiene), 19, 270-289 (1962).⁷

Submitted on 16 February 1962 on the basis
of data collected at the Sanatorio Antitu-
berculoso "Venezuela" and the Instituto de
Anatomia Patologica de la Universidad de Los
Andes, Merida (Venezuela).

Introduction

In spite of all precautionary measures, histoplasma capsulatum in-
fections occur quite frequently in mycological laboratories, as reported by
Grayston and Salvin, among others. Furcolow, Guntheroth, and Willis, Dickie
and Murphy, as well as Loosli have reported on clinical aspects of these in-
fections. Several well-known mycologists in the United States, among them
Emmons and Procknow, assure us that prolonged work with this fungus will re-
sult in infection very frequently. Since the disease was mild in most cases
and fatalities resulting from occupational exposure had not occurred hereto-
fore, infection occurring during research of this fungus had been considered
as almost unavoidable. Our experience has shown that, under certain special
circumstances, such an infection may be fatal. We therefore wish to report
on such a case in which, additionally, anatomical findings were made which,
to our knowledge, heretofore have not been reported in connection with such
cases of fatal histoplasmosis.

^WDedicated, on the occasion of his 70th birthday, to Prof. Dr. med, Dr.h.c.
E. W. Baader.

Case Report

Summary of Case History

A 45-year old Italian mycologist, a resident of Venezuela for the past 4 years, had been engaged primarily in investigations of *histoplasma capsulatum* over a period of approximately one year. Soil samples from various regions of the Venezuelan Andes, usually obtained from chicken coops, after special treatment in his laboratory, were injected into the abdominal cavity of white mice in the form of a suspension. After a certain period of time, pieces of the liver and spleen of the animals were transferred to a nutrient medium; in a certain percentage of cases, the fungus began to grow in the tissue. Smears of the fungi grown in these cultures were then prepared by the mycologist without the aid of any protective measures. In April, 1960, some 6 months after the start of the above investigations, a histoplasmin skin test given to the mycologist turned out to be negative. Up to that point, very few positive fungus cultures had been obtained.

Family Anamnesis

Both the brother (at age 37) and the mother (at age 70) of the patient succumbed to a heart infarct.

Patient's Anamnesis

As a child, the patient had scarlet fever, chicken pox, and mumps. At the age of 10, he spent considerable time in the hospital with exudative pleurisy and, at the age of 20, he was hospitalized for a three-month period with severe double pneumonia. At the age of 30, while a prisoner of war in India, he contracted malaria, but was completely cured. During the same year he underwent a double tonsillectomy, having suffered frequently from tonsil infections and chronic abscesses of the middle ear. At the age of 40 he developed a duodenal ulcer which responded to conservative treatment.

Present Illness

The patient's last contact with infectious material was on 11 October 1960, when he visited his laboratory to examine numerous fungus cultures. On the following day, in the company of four other persons, he visited a limestone stalactite cavern on the western slope of the Venezuelan Andes. There, as well as in chicken coops of farms in the vicinity, he obtained several soil samples.

On 24 October 1960, twelve days later, the patient became ill. With the exception of dyspnea following physical exertion, the patient had been in good health during the past few years. His present illness manifested itself in general malaise, sore throat, occasional coughing with minor mucous expectoration, and a temperature of 37 to 38 degrees. When the patient did not show any improvement, his physician, called on the third day of the illness, made the following findings:

The patient, of pyknic body type, was in good general health and in a good state of nutrition, somewhat corpulent, weighing 79 kg and being 1.67 m tall. Body temperature 38.3°, pulse 100/min, blood pressure 130/90 RR. The pharyngeal mucous membrane was diffusely reddened, with minor mucopurulent deposits. Postoperative condition, bilateral tonsillectomy. Both tympanic membranes sclerotically changed and cicatricially contracted, with hearing impaired. Percussion and auscultation of chest -- no particular findings. In addition to the complaints listed above, the patient complained of occasional coughing and a stabbing pain in the right side of his chest when taking a deep breath.

When, after combined treatment with sulfonamides, tetracycline, and vitamins, the patient had not completely recovered on the 5th day of his illness, a new histoplasmin skin test (0.1 cm²; 1:100) was performed, in view of the patient's known exposure in the laboratory. Test results, with a diameter of 15 mm, were positive. During those days, minor leukocytosis with normal differential blood picture and accelerated BSG were determined. Blood data for the entire course of the illness appear in the table below.

The chest x-ray (Figure 1) on the 10th day of illness showed two poorly defined, hazelnut-sized shadowy areas of irregular density at the level of the 5th intercostal space on the right and the 6th on the left. In the right lower field, a slightly larger, irregularly defined shadowy area of little density, but with stripe-like marking, could be seen. In addition, the lungs appeared sharply defined, with fine-grained shading on both sides. Hili were clearly multiplied and thickened. The right upper interlobar space appeared as a thin line delineating the outer third.

The positive histoplasmin test and the x-ray examination, together with the elevated BSG, in view of the patient's previous history, led to a diagnosis of pulmonary histoplasmosis.

TABLE. Principal hematological findings during the course of the disease

Day of disease	leuko-cytes	Segment neutrophils	Eosino-philes	Lympho-cytes	Erythro-cytes in mill.	Hb g.%	BSG
10th	8,200	62	0	29	4.66	14.34	34/67
16th	6,850	56	1	36	4.50	13.36	35/79
23rd	7,200	57	1	40	4.42	13.34	34/70
36th	10,500	62	2	33	4.34	13.25	40/84
39th	10,100	75	2	14	4.12	12.7	78/34
41st	8,600	57	5	37	4.0	12.3	45/78
45th	5,500	51	4	41	4.1	12.7	48/88
50th	8,700	67	5	25	4.06	12.5	42/87

Since the patient had refused stationary treatment, he received ambulatory treatment from the 10th through the 33rd day of illness. Throughout that time, he had no fever, voiced no subjective complaints, and displayed a good appetite. It was difficult to get him to follow the physician's order for bed rest. The patient insisted on continuing his laboratory work. On the 23rd day of sickness, a blood sample was taken for serological examination. While the complement fixation reaction for the mycelia and conidiform of the *paracoccidioides brasiliensis* turned out to be negative, the titer for *histoplasma capsulatum* at 1/64 was distinctly elevated. These values remained unchanged in two subsequent examinations on the 30th and 50th day of sickness.

Throughout the remaining course of the disease, the patient was daily treated with 4 g Elkosin and 6 Dragees Ferronicum, while polyvitamin therapy was being continued.

During the course of the ambulatory treatment we had gained the impression, from x-ray control examinations performed weekly, that the initially observed infiltrates began to be delineated with increasing sharpness. The sharp delineation of the lungs with fine-grained shading, noted at first, subsequently became less clear. Swelling of both hili remained undiminished. Percussion and auscultation of the thorax did not indicate disease. Liver and spleen were not enlarged. Results of urine analysis were normal; however, blood sedimentation rate remained high, number of leukocytes in peripheral blood was slightly decreased, and slight anemia developed.

Stationary Treatment

On the 34th day of sickness, the patient, having assisted in bathing the children, had become heated and had exposed himself to a draft. On the following day he again complained of being indisposed, fever, and heart palpitation, as well as breathing difficulty and a stabbing pain in the right side of his chest. In spite of these complaints, patient had not remained in bed. The physician was notified of this worsening of the patient's condition only on the following day. Examination on the 36th day of sickness showed dyspnea and tachycardia of 130 with well-filled pulse and occasional extrasystoles. In view of the sudden turn for the worse, stationary treatment of the patient was ordered on the 37th day of sickness. During admission, the patient had no temperature, showed tachycardia of 130, and blood pressure of 120/90 RR. Dyspnea was clearly evident with an indication of cyanosis of the lips, as well as coughing with slight mucous expectoration. Over both lower lung fields, medium bubbling rale was determined during broncho-vesicular breathing and normal vocal fremitus. The x-ray showed increased vascular delineation, particularly in the right lower field.

* We are indebted to Dr. G. A. Maeckelt, Profesor del Instituto de Medicina Tropical de la Universidad Central de Venezuela, for these examinations.

Auscultation of the heart showed no abnormal sounds. The electrocardiogram showed a low T and an indicated deep ST. The Q-spike in the 1st and 2nd extremity derivation was 1 and 1.5 mm deep and of short duration. No swelling of the liver or spleen, no jugular congestion or edema could be found.

The leukocyte count had increased to 10,500, and an increase in the blood sedimentation rate was determined.

Under oxygen therapy and medication of 0.4 g Chinidine as well as Reverine intravenously injected, the extrasystoles and cyanosis disappeared immediately, pulse frequency dropped to 100 within a few hours, and to 90 on the following day. Electrocardiogram taken over the next few days failed to show any pathological condition. The glutamic acid-oxalacetic acid-transaminase value, on the 38th, 39th, and 40th days of sickness was 30, 17, and 14 E/ml.

From the 3rd day of stationary treatment (39th day of sickness), auscultation of lungs and heart and large vessels did not indicate any abnormal condition. Coughing and expectoration did not occur any more. During the following days no indications of congestion were noted. Dyspnea subsided after bed rest. Heart frequency varied between 80 and 90/min and blood pressure remained constant at 120/90 RR. During the course of stationary treatment the patient never had any fever.

On the 41st day of sickness, the leukocyte count in peripheral blood had decreased and the blood sedimentation rate had dropped. No gall pigments could ever be determined in urine analyses.

Control x-rays (Figures 2 and 3), taken on the 43rd and 44th days of sickness, indicated two soft, irregularly defined and partially confluent shaded areas, about 2 cm in diameter, in the right upper field. These areas were situated beneath the pleura and were partially obscured by the first rib.

After being ordered to bed, the patient had felt increasingly better and in the last days had voiced no subjective complaints. On the 51st day of sickness, after the patient had arisen to wash in the morning and after he had had his breakfast out of bed, death occurred suddenly when the patient arose again in order to seat himself in his wheelchair for the trip to the x-ray room.




Figure 1

Figure 2

Figure 3

Figure 1: X-ray of the thorax on the 10th day of sickness.

Figure 2: X-ray of the thorax on the 43rd day of sickness. The three shaded areas seen in Figure 1 have diminished in size and are more sharply delineated. Shaded area in right upper field is partially obscured by the 1st rib and the clavicle.

Figure 3: Stratum view of right lung at a depth of 8 cm on the 44th day of sickness. Visible in the right upper field are two partially confluent shaded areas, irregularly defined.

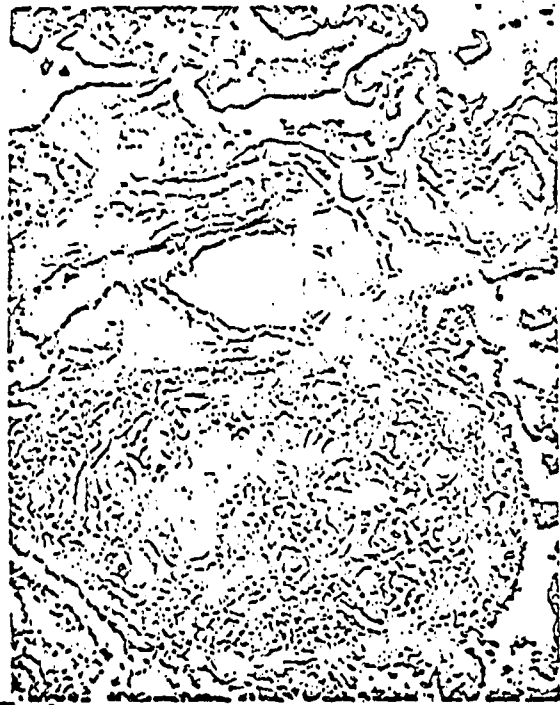


Figure 4: H-E stain; 115 x; Tuberculoid granuloma in the adventitia of a lung artery with cell infiltration of a vessel wall.

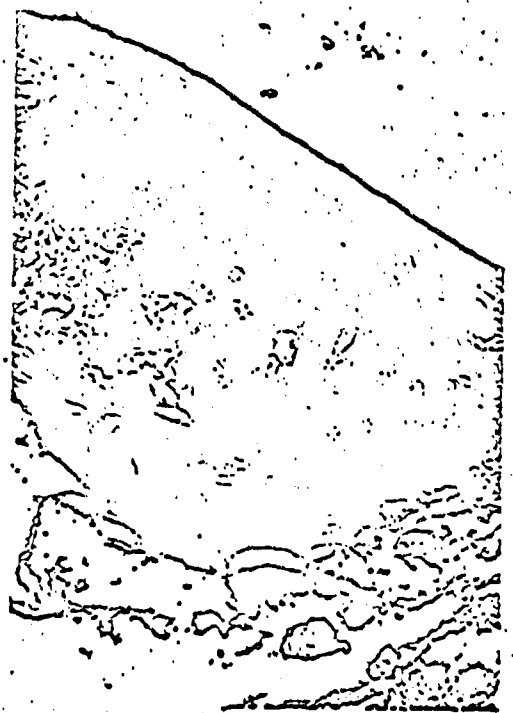

Figure 5: Ferrous hematoxyline; 115 x; Tuberculoid granuloma with extension to the wall of an erythrocyte-filled vein in the lung.



Alb. 6



Figures 6, 7, and 8: Ferrous hematoxyline; 30 x, 72 x, and 300 x;
Various enlargements of the same artery. Organized arterial thrombosis
with small residual lumina in a lung infarct. At various points in the
adventitia, granulomas with necroses and extension of these to the arterial
wall. Figure 8 shows an enlarged tuberculoid granuloma with two giant cells
in the adventitia.

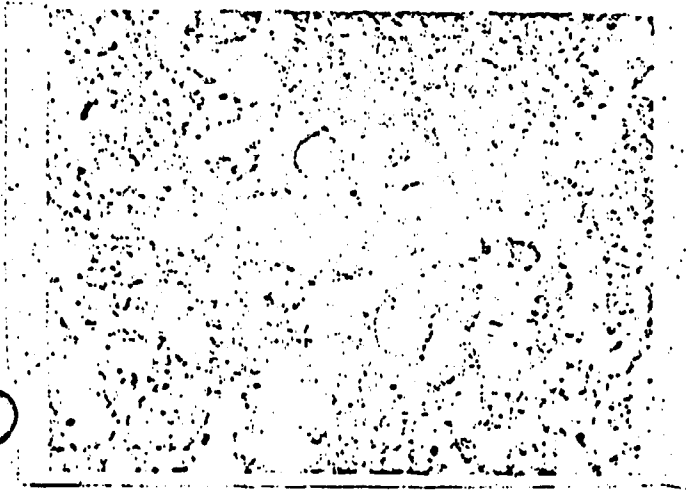


Figure 9: C.M.S. stain; 1,800 x; Conidia in the caseous zone of one of the larger subpleural foci.




Figure 10: G.M.S. stain; 1,500 x; Conidia in a caseous granuloma of the adventitia of the thrombosed artery (see Figures 6-8).




Figure 11: Ferrous hematoxyline stain; Figure 12: H-E stain; 95 x;
1,150 x; Giant cell with vacuoles. Tuberculoid granuloma in a lymph
node of the lung hilus.
Here we are not dealing with histoplasmae.

Clinical Summary

An early diagnosis of fungus disease was arrived at clinically after a second histoplasmin test turned out to be positive (following a first test which was negative). Subsequently, the complement fixation reaction, too, was positive. Following the patient's death, histoplasma capsulatum was grown in sputum cultures, started at the beginning of stationary treatment. X-ray examination showed no solitary primary center, but multiple infiltrates in the lungs and bilateral hilus swelling.

Initially, the prognosis was good. Based on lung X-rays, the indication was that this was a case of histoplasmosis with relatively sparse distribution. During the course of the sickness, only slight anemia was diagnosed and the blood sedimentation rate was constantly elevated. Even after the sudden symptoms which resulted in stationary treatment beginning in the fifth week after the start of sickness, there appeared to be immediate improvement, and the patient continued to feel well up to his sudden death.

Clinical interpretation of the sudden symptoms on the 35th day of sickness was very difficult. In addition to thinking of a renewed histoplasmosis distribution in the lung, we thought of an unspecific pneumonia infection, then of a heart infarct, or of a distribution of the histoplasmosis in the heart muscle. The latter two complications had to be excluded on the basis of the electrocardiogram and the course taken by the sickness. Symptomatology was not characteristic of a lung infarct. When death occurred suddenly and unexpectedly, we thought of a lung embolism or a heart infarct.

Immediately after the diagnosis had been made, the patient was subjected to Elkosin treatment, in view of the known tolerability of this sulfonamide preparation. In addition to sulfonamide medication, treatment of histoplasmosis cases with amphotericin B (Fungizone, Squibb) is recommended. Immediately upon arriving at a diagnosis we contacted the Squibb representative in Caracas by wire; we were told, however, that this preparation had been withdrawn from the market. We found it impossible to obtain this medication through friends in Caracas and in the United States.

Summary of Postmortem Report

Only the organs of the chest and abdominal cavities could be examined 12 hours after death, since the body of the deceased had to be prepared for overseas shipment.

The following macroscopic determinations were made: pyknic habitus; good state of nutrition with corpulence. Skin and natural body openings without pathological findings. Rigor mortis present; extended livor mortis in the suspended parts. Bluish-red discoloration of the skin in the upper parts of chest, neck, and head.

Chest Organs

The lungs, particularly in the middle and lower sections of both thoracic cavities, show cordlike adhesions with the thoracic wall. They are voluminous and show a pleura with smooth surface. Knots of various sizes can be identified by feeling both organs. In section, the lung tissue appears partially porous, with extended zones of increased consistency, dark red in color, which, under pressure, yields a red foamy liquid.

In the left lung there are three and, in the right lung, two round, well-delineated foci, located primarily in the immediate vicinity of the pleura; in section they appear gray-yellowish and show increased consistency. The area of these foci varies from 4 to 7 mm in diameter. The section surface which indicates a concentric stratification does not lend itself to stripping. In addition to the larger subpleural foci, very small dot-shaped foci, grayish-white in color, can be identified on lung section surfaces. They are most clearly seen on the left inferior lobe and occur only rarely in the other lung lobes. Sections of the left lung show several dark red, not clearly delineated zones, up to 3 cm in diameter. In the right lung, there are a total of 3 subpleural cone-shaped reddish-gray foci, sharply defined, up to 2 cm in diameter; two of these are in the superior lobe, and one is in the inferior lobe. Section of the lung base showed, on the left, dark red-gray, semi-rigid masses of irregular surface, encountered during the opening of the pulmonary arteries, in the region of the first branching of the arteries; these masses were adhering to the arterial wall. In the stem of the right pulmonary artery similar masses were found; these were opaque and adhered to the arterial wall even more strongly.

Hilus lymph nodes on both sides were considerably enlarged, firm, and grayish-black in color. Sections showed grayish-white, firm foci, irregularly delineated and 2-5 mm in diameter.

The heart is of proper size, with an abundance of fatty tissue of the epicardium. Section shows heart muscle irregularly outlined against fatty tissue. Consistency of heart muscle is flabby. Vertical walls are thin, about 4 mm on the right and 8 mm on the left. Heart valves, endocardium, and heart auricles normal. Coronary arteries are quite wide, with small, barely prominent yellowish papillae in the tunica interna. Section shows in the left ventricle a spotty delineation of the myocardium.

Abdominal Organs

The peritoneum is mirror-smooth; organs are properly located. Revision of the intestinal loops indicates that the mesenterium, full of fatty tissue, and the retroperitoneal fatty tissue are thickened by tumor-like bulges and look as if boiled. A moist, gelatinous tissue is encountered, with large nodes, yellowish in color, which, in section, shows grayish-white areas. No lymph nodes are detected.

Spleen

The spleen is of proper size and has a smooth surface. In section, the pulpa appears grayish-red in color, and is of vary soft, jelly-like consistency. Under the capsule and in section, individual pinhead-sized grayish-white foci can be identified.

Liver

The liver is of proper size and consistency, has a smooth surface, and is reddish-brown in color. Individual, irregularly defined yellowish zones and individual, small, grayish-white foci can be identified in section. Gall bladder and bile ducts are normal.

The kidneys are grayish-red in color, of proper size, and show individual star-shaped contractions on the surface. Individual grayish-white foci, such as encountered in the spleen and liver, can be determined. Stomach, intestines, pancreas, adrenal glands, and pelvic organs are normal. Macroscopic diagnosis was as follows: Five caseous foci, up to 0.7 cm in diameter, not too fresh, and minor diffuse distribution of submiliar granulomas in both lungs, most distinctly in the left inferior lobe.

Small caseous foci and granulomas in the enlarged hilus lymph nodes on both sides.

Thrombosis of pulmonal arteries in both lungs; more fresh in the first branches on the left, not quite fresh in the main stem on the right.

Several extended infarct-like hemorrhages in the left lung, and three hemorrhagic, not-too-fresh infarcts in the right lung. Lung edema on both sides.

Cordlike pleura growths on both sides. Minor distribution of submiliar and miliar granulomas in liver, kidneys, and spleen. Septic spleen. Focal adiposis of the liver. Irregular greyish-white delineation of heart muscle in back wall of left ventricle. Adipositas cordis. Edema and fat necrosis in mesenterium and retroperitoneum.

Microscopic examination was performed of lungs and main stem of pulmonal arteries, hilar and peribronchial lymph nodes, heart muscle, liver, pancreas, adrenal glands, mesenterium, and retroperitoneum. Stains used: H-E, ferrous hematoxyline, fibrin (Weigert), Goldner, PAS (Braun-Falco), Mucicarmin, Ziehl-Neelsen, and G. M. S. (see Manual of Histology and Special Staining Techniques, Armed Forces Institute of Pathology, Washington, D. C., 1957).

Lungs

Examination shows a fibrosis in the form of small circumscribed foci, frequently subpleural, and fibrous pleura thickening. Large and medium-sized pulmonary arteries show sclerotic intima indurations. In many places, edema and extended fresh bleeding can be observed. Many sections of various parts of lung tissue, particularly near the bronchi and blood vessels, show submiliary and miliary granulomas with epithelioid cells, giant cells, and lymphocyte infiltrates, which frequently indicate a central necrosis. Further, supramiliary fresh caseous foci are observed occasionally. Perivascular localization of the granulomas shows that the latter occasionally extend to the vessel wall (see Figures 4 and 5).

The five larger subpleural foci histologically show a similar picture: there are caseous foci, surrounded by specific granulation tissue with numerous giant cells. A cluster arrangement is apparent: almost completely anuclear necrosis masses which, when stained, appear red, alternate with portions rich in nuclear fragments. Both in the foci and in the peripheral areas collagenous connective tissue, frequently arranged in shell form, is noted. Demarcation between the connective tissue and surrounding lung tissue is quite sharp, but there is no continuous fibrous capsule. In the vicinity of several of the foci there are traces of recent bleeding as well as individual granulomas, or groups of granulomas, both submiliary and miliary, as described above.

Foci in the right lung, macroscopically diagnosed as infarcts, do not correspond to fresh hemorrhagic infarcts. In these, specific granulomas and small caseous foci can be recognized. In one of the infarcts which was examined in step sections, an almost completely obliterating organized thrombosis of a pulmonary artery branch with small residual lumina was found (Figures 6 through 8). Here, also, there were found caseous foci and specific granulomas in the immediate vicinity of the vessel wall with extension to the artery wall and necrosis of the latter.

Acid- and alcohol-resistant bacilli were not found anywhere. However, in the caseous foci and granulomas, under G. M. S. stain, numerous conidia, round or oval, clearly delineated and appearing black in coloration, could be observed (Figures 9 and 10). Their diameter ranged from 3 to 6 microns and they were arranged individually, in small groups, or in chains. Conidia in large numbers could be observed in the necrotic regions and only singly in zones of the granulation tissue; in giant cells they occur only singly. Groupings of conidia were seen both in the perivascular specific caseous foci as well as in the organized thrombus masses of the artery depicted in Figures 6 through 8 (Figure 10).

In the paraffin-embedded material no double refraction of the conidia can be determined, and the mucicarmin stain is negative. Fungi could be observed only in the G. M. S. stain. In the cytoplasm of several of the giant cells, the H. E. stain showed numerous vacuole-like structures (Figure 11) which reminded us of the classic forms of histoplasms with shrunken nuclei. These structures never assumed black coloration in section under G.M.S. stain.

Pulmonary Arteries at the Base of the Lungs

Not quite fresh thrombosis with indications of organization and considerable cell infiltration in the arterial wall and its vicinity. On the left side, thrombosis is more recent and shows less organization.

Hilar and Peribronchial Lymph nodes

Here, caseous foci with specific granulation tissue and granulomas of various sizes are found (Figure 12). In the center and the periphery of the foci, collagenous connective tissue can be identified. Like in the lungs, tissue changes here cannot be distinguished from tubercular tissue changes. Here, too, the fungus is found, as was the case in the foci of the lung tissue.

Liver, Kidneys, and Spleen

Submiliary and miliary tubercular granulomas in small numbers, in which the fungus can be identified occasionally.

Heart Muscle

Moderate adipositas cordis with atrophy of heart muscle fibers. Minor sclerosis of intramural arterial branches and perivascular fibrosis. In some areas edema and circumscribed fresh bleeding is noted. In some areas, fresh fatty tissue necroses with minor infiltration of leukocytes and bleeding are seen in the subepicardial fatty tissue. No granulomatic changes.

Pancreas

In many areas, zones of various size, with autolytic changes of the parenchyma. At some points of the interstitial fatty tissue, circumscribed necroses with infiltration of individual leukocytes.

Mesenterium and Retroperitoneal Fatty Tissue

In the fatty tissue there are lymphocyte collections of various size which, in some spots, permit recognition of follicles and lymph nodes. In addition, there are zones of various size of fresh fatty tissue necrosis with leukocyte infiltration and small bleeding.

Adrenal Glands

No pathological findings.

Epietisis

We are dealing here with a case of histoplasmosis-primary infection, in which the fungus caused tissue changes in lungs, lymph nodes, liver, kidneys, and spleen. Since only a partial postmortem was performed, we are limited to the findings of this postmortem in our interpretation of the case. The source of infection will be treated in the discussion.

From the initial appearance of the symptoms of the disease until death of the patient there elapsed a period of seven weeks. A histoplasmine skin test performed six months prior to the appearance of the initial symptoms turned out to be negative; however, a second skin test made during the initial days of the illness was positive. In addition, the complement fixation reaction was positive and the fungus could be demonstrated in the sputum.

The granulomatous lung changes, as well as the larger subpleural foci and the fine distribution, were only indicated in x-rays. This is understandable since, anatomically, these were rather fresh foci which did not yield much contrast. On the other hand, x-rays showed two changes in the right upper lobe, later identified as infarcts, which were difficult to diagnose as such at the start. Clinically, these infiltrates were at first thought to be histoplasmosis foci, while the attack-like dyspnea with circulation symptoms was interpreted as acute cardiac insufficiency resulting from myocardium damage caused by histoplasmosis distribution or hypoxemia changes.

Based on the anatomic picture, the larger and smaller histoplasmosis foci in the lung obviously were changes of equal age. No solitary older primary focus was found in the lungs: thus, the five larger subpleural foci must be considered as multiple primary foci, from which, secondarily, but rather quickly a lymphogenous and/or hematogenous distribution in the lungs occurred. Another possibility would be that all histoplasmosis foci were established in the lungs at the same time, through inhalation. We shall return to this subject in the discussion.

The sparse histoplasmosis granulomas in liver, kidneys, and spleen are somewhat more fresh and obviously the result of a hematogenous distribution originating in the lung- or lymphnode-foci.

Pathogenetically, how are the vessel changes in the lungs and their consequences to be interpreted? A clearly perivascular localization of the granulomas must have existed in the early stages of development of the pulmonary histoplasmosis, which rapidly brought about changes in the vessel walls, formation of thrombi in the middle and small pulmonary artery branches, and infarcts. Even though slight lung artery sclerosis was diagnosed and the possibility of embolisms cannot be excluded, it is our belief that the occurrence of thrombosis was brought about directly as a result of the perivascular histoplasmosis foci which extended into the vessel walls.

More difficult is an explanation of the formation of thrombosis in the primary stems of the pulmonary artery. No granulomatose changes in the adventitia or the arterial walls were found, as was the case in the medium-sized arterial branches. Instead, we must think of several formation mechanisms that came into play concurrently: if thromboses already existed in the medium-sized arterial branches, there may have occurred retrograde changes in the blood flow ratios in the larger arterial branches; further, changes in the blood itself may have occurred, in view of the existing infection; in addition, the hilus lymph node swellings could have -- as a result of compression -- contributed to the intravascular blood coagulation. The changes in the arterial wall and in the thrombus masses in the vicinity of the tunica interna indicated that the process here had started some time ago. It may be assumed that, beginning with minor parietal thrombotic aggregations, blood coagulation, over a period of time, proceeding progressively in the direction of the lumen, finally blocked the arterial clearance completely.

The patient's arising in the morning may, as a sudden circulation load, have caused the acute insufficiency of an already overloaded and damaged heart muscle, which would serve as an explanation of his sudden death.

Discussion

It is not quite clear how the infection came about in the case under discussion. Together with four other persons, the patient visited -- 12 days before the appearance of the first symptoms -- a cavern and personally took several soil samples from the cavern and from several chicken coops in the vicinity. Histoplasmae could be shown to have been present in two of these samples (in one sample of a total of four samples taken from the cavern, and in one of the samples taken from a chicken coop); this means that relatively few microorganisms were contained in the soil of the cavern. Moreover, none of the four persons who accompanied the scientist to the cavern took sick, and their histoplasmin skin tests gave negative results. Of course, they did not come into close contact with the soil. Thus, it cannot be completely ruled out that infection took place on the day of the visit to the cavern. Histoplasmosis infections resulting from visits to caverns are known to have occurred in our country (Campins, Zubillaga, Gomez Lopez and Dorante); in the course of such excursions, a larger number of participants took sick, but no fatalities are known to have occurred.

In our opinion, another possibility appears more likely: it is that the patient infected himself in the course of examining the numerous histoplasma capsulatum cultures in his laboratory. Particularly many cultures were grown during the weeks immediately preceding his illness; in all cases, the patient personally examined the cultures and took smears. Infection through inhalation of elements of fungus cultures appears the more likely since the postmortem showed the distribution of the histoplasmosis changes with apparently multiple primary foci and the localization of many foci in the vicinity of the bronchi and vessels. Procknow, Page, and Loosli, in experiments with animals in which causative agents from fungus cultures (mycelia, chlamydo-spores, and conidia) were applied intratracheally, noted a pronounced peri-

bronchial localization of the tissue changes resulting from fungus infection. The mycelia and chlamydo-spores used to induce infection could be demonstrated for a period of only two weeks following infection. These fungus elements disappear and, in later stages, only the conidia can be seen in the tissue. Thus, in our case, the presence of mycelia and chlamydo-spores -- which would have proved infection in the laboratory -- at a point more than 7 weeks after infection was not to be expected.

The literature notes that in a large percentage of histoplasmosis cases x-rays show multiple nodular infiltrates (Conant and associates) or diffuse node-shaped shaded areas in the so-called "acute epidemic variety" (Furcolow and Rubin, also Herron and Furcolow). Similar x-ray findings, even though not as strongly defined, were made in our case.

In contrast, the claim is made on the basis of pathological-anatomical determinations that initial infection in histoplasmosis cases results in changes, in the sense of a primary complex, that are similar to those occurring in tuberculosis (Puckett; Straub and Schwarz). The latter authors found that the lung foci in primary infection with histoplasmosis are generally somewhat larger than those in tuberculosis.

This discrepancy between clinical and pathological-anatomical data may be based on the fact that heretofore only few of the acute cases of histoplasmosis with multiple nodular infiltrates at that stage of development have been submitted for pathological-anatomical examination. Pathologists generally are more likely to see surgical material with so-called histoplasma.

Further, it is worthy of note that serious or fatal cases of histoplasmosis in our country have been described primarily in cases of foreign-born patients (Angulo; Salfelder), particularly older persons. Natives, particularly country people, apparently undergo a clinically not determinable or a benign infection in their youth. A massive infection in the case of immigrants who had never come in contact with the fungus, is much more likely to result in death. In the United States, too, fungus infections are reported in the wake of settlement in histoplasmosis endemia regions; in the case of immigrants -- in contrast with the native population -- such infections frequently result in clinical manifestations (Baum and Schwarz).

The literature does not report on cases of histoplasmosis with localization of the granulomes in the lungs in the vicinity of the vessels, extension to the vessel walls, and formation of thrombi. Such changes could be designated as thrombarteriitis histoplasmotica. In the course of a visit to the Mayo Clinic we heard that Bahn, in a number of cases of generalized histoplasmosis with adrenal gland changes, found extended necroses in these organs. These necroses could apparently be traced to vessel changes with thrombi, caused by fungus granulomes. Further, there is a report by Sutliff of a fatal case of pulmonary histoplasmosis which contains a comment about chronic pulmonary arterial thrombosis, but no particular comment is made on a connection between histoplasmosis and the vessel changes.

Cases are known of chronic mediastinitis through histoplasmosis in which compression of large vessels may occur (Lull and associates; Salyer and associates). In one of our cases (A 2153; 65 b) we saw a cor pulmonale with extended, diffuse, calcified and ossified histoplasmosis foci in both lungs. In cases of chronic histoplasmosis, only Sutliff notes a single case of a finding of cor pulmonale; on the other hand, lung changes in histoplasmosis in connection with, or as a possible cause for cor pulmonale, are not noted in the summary presentation of Schepers.

As far as the cause of death in histoplasmosis cases is concerned, one generally observes a septic-toxic clinical picture with cachexia, enlargement of the liver and spleen, and insufficiency of the RES (Wail; Peabody; Furcolow and Brasher; Sutliff; Curry and Wier). In the majority of cases, death follows increasing deterioration with extended generalization. In our case, the only possible explanation for the sudden death is the above-mentioned circulatory complication. This would appear to be an unusual and rare occurrence, since the disease took a generally benign course with moderate distribution in the lungs and minor distribution in other organs. With the exception of the elevated blood sedimentation rate and the slight anemia, there were no signs of toxic damage. In view of the subsequent fever-free course and the general lack of complaints, the fatal outcome could not have been anticipated at all.

The massive, apparently gradually built-up thrombosis of the primary stems of the pulmonary artery had been preceded by no symptoms and therefore had not been clinically diagnosed.

The fresh fatty tissue necroses in our case were most prominent in the mesenterium and the retroperitoneal fatty tissue, less prominent in the pancreas interstitium and in the subepicardial fatty tissue. Moreover, pathological-anatomical changes of the parenchyma of the pancreas were not clearly recognizable; it should be noted that autolytic changes had already occurred. It is known that fatty tissue necroses can occur independently and in acute fatal cases (Guethert). On the other hand, the literature contains little exact data on its possible role as a causative factor in cases of death. The origin of the necrosis in our case is not clarified. We should not like to discard the possibility that it may have had a part in the occurrence of the pulmonary artery thrombosis or of the shock.

Bibliography

Angulo, Ortega A.: Personal Communication.

Bahn, R. C., Mayo Clinic publication scheduled to appear in 1962.

Baum, G. J., and J. Schwarz, Pulmonary histoplasmosis, *New Engl. J. Med.*, 258, 677 (1958).

Bronson, S. M., and J. Schwarz, Roentgenographic patterns in histoplasmosis, *Amer. Rev. Tuberc.*, 76, 173 (1957).

Campins, H., C. Zubillaga, L. Gomez Lopez, and M. Dorante, Estudio de una epidemia de histoplasmosis en el Edo. Lara (Venezuela). *Gac. med. Caracas*, 62, 85 (1955).

Conant, N. F., D. T. Smith, R. D. Baker, and J. L. Callaway, Manual of clinical mycology. W. B. Saunders Company, Philadelphia and London, 1959.

Curry, F. J., and J. A. Wier, Histoplasmosis. A review of one hundred consecutively hospitalized patients. *Amer. Rev. Tuberc.*, 77, 749 (1958).

Dickie, H. A., and M. E. Murphy, Laboratory infection with *histoplasma capsulatum*; notes, *Amer. Rev. Tuberc.*, 72, 690 (1955).

Emmons, C. W., Personal Communication.

Furcolow, M. L., and C. A. Brasher, Chronic progressive (cavitary) histoplasmosis as a problem in tuberculosis sanatoriums. *Amer. Rev. Tuberc.*, 73, 609 (1956).

Furcolow, M. L., W. L. Guntheroth, and M. I. Willis, Frequency of laboratory infections with *histoplasma capsulatum*: Their clinical and X-ray characteristics. *J. Lab. clin. Med.*, 40, 182 (1952).

Furcolow, M. L., and H. Rubin, The clinical recognition and treatment of histoplasmosis, blastomycosis, and cryptococcosis. *Trans. 5. Internat. Congr. Disear. Chest.*, Tokyo, 7 Sept. 1958, p. 252.

Grayston, I. T., and S. B. Salvin, Experimental histoplasmosis in immunized and non-immunized mice. *Arch. Path (Chicago)*, 61, 422 (1956).

Guethert, H., Textbook of special pathological anatomy of Kaufmann-Staemmler, vol. II/2, Berlin: W. de Gruyter, 1958.

Harron, J. T., and M. L. Furcolow, Histoplasmosis in Arkansas. *J. Ark. med. Soc.*, 55, 194 (1958).